


Use of patient derived orthotopic xenograft models for real-time therapy guidance in a pediatric sporadic malignant peripheral nerve sheath tumor

Juana Fernández-Rodríguez*, Andrés Morales La Madrid*, Bernat Gel, Alicia Castañeda Heredia, Héctor Salvador, María Martínez-Iniesta, Catia Moutinho, Jordi Morata, Holger Heyn, Ignacio Blanco, Edgar Creus-Bachiller, Gabriel Capella, Lourdes Farré, August Vidal, Francisco Soldado, Lucas Krauel, Mariona Suñol, Eduard Serra, Alberto Villanueva** and Conxi Lázaro** 

Abstract

Background: The aim of this study was to test the feasibility and utility of developing patient-derived orthotopic xenograft (PDOX) models for patients with malignant peripheral nerve sheath tumors (MPNSTs) to aid therapeutic interventions in real time.

Patient & Methods: A sporadic relapsed MPNST developed in a 14-year-old boy was engrafted in mice, generating a PDOX model for use in co-clinical trials after informed consent.

SNP-array and exome sequencing was performed on the relapsed tumor. Genomics, drug availability, and published literature guided PDOX treatments.

Results: A MPNST PDOX model was generated and expanded. Analysis of the patient's relapsed tumor revealed mutations in the *MAPK1*, *EED*, and *CDK2NA/B* genes. First, the PDOX model was treated with the same therapeutic regimen as received by the patient (everolimus and trametinib); after observing partial response, tumors were left to regrow. Regrown tumors were treated based on mutations (palbociclib and JQ1), drug availability, and published literature (nab-paclitaxel; bevacizumab; sorafenib plus doxorubicin; and gemcitabine plus docetaxel). The patient had a lung metastatic relapse and was treated according to PDOX results, first with nab-paclitaxel, second with sorafenib plus doxorubicin after progression, although a complete response was not achieved and multiple metastasectomies were performed. The patient is currently disease free 46 months after first relapse.

Conclusion: Our results indicate the feasibility of generating MPNST-PDOX and genomic characterization to guide treatment in real time. Although the treatment responses observed in our model did not fully recapitulate the patient's response, this pilot study identify key aspects to improve our co-clinical testing approach in real time.

Keywords: exome sequencing, MPNST, PDOX model, personalized medicine, SNP-array, targeted drug treatment

Received: 28 November 2019; revised manuscript accepted: 1 May 2020.

Ther Adv Med Oncol

2020, Vol. 12: 1–11

DOI: 10.1177/
1758835920929579

© The Author(s), 2020.
Article reuse guidelines:
sagepub.com/journals-
permissions

Correspondence to:

Conxi Lázaro
Hereditary Cancer
Program, Catalan Institute
of Oncology, IDIBELL and
CIBERONC, Av. Gran Via
199-203, Hospitalet de
Llobregat, 08908, Spain

Program in Molecular
Mechanisms and
Experimental Therapy
in Oncology (Oncobell),
IDIBELL, Hospitalet de
Llobregat, Barcelona,
Spain

Centro de Investigación
Biomédica en Red de
Cáncer (CIBERONC), Spain
clazaro@iconcologia.net

Alberto Villanueva
Procure Program,
Catalan Institute of
Oncology, Hospitalet de
Llobregat (Barcelona) and
CIBERONC, Av. Gran Via
199-203, Hospitalet de
Llobregat, 08908, Spain

Program in Molecular
Mechanisms and
Experimental Therapy
in Oncology (Oncobell),
IDIBELL, Hospitalet de
Llobregat, Barcelona,
Spain

Xenopat S.L., Business
Bioincubator, Bellvitge
Health Science Campus,
08907 L'Hospitalet de
Llobregat, Barcelona,
Spain
avillanueva@iconcologia.net

Juana Fernández-Rodríguez
Gabriel Capella
Hereditary Cancer
Program, Catalan Institute
of Oncology, IDIBELL,
Hospitalet de Llobregat,
Barcelona, Spain

Program in Molecular
Mechanisms and
Experimental Therapy
in Oncology (Oncobell),
IDIBELL, Hospitalet de
Llobregat, Barcelona,
Spain

Centro de Investigación
Biomédica en Red de
Cáncer (CIBERONC), Spain

Andrés Morales La Madrid
Alicia Castañeda Heredia
Héctor Salvador

Pediatric Oncology
Department, Hospital Sant
Joan de Déu, Barcelona,
Catalunya, Spain

Bernat Gel
Eduard Serra
Centro de Investigación
Biomédica en Red de
Cáncer (CIBERONC), Spain

Hereditary Cancer Group,
Germans Trias i Pujol
Research Institute (IGTP)-
PMPPC; Can Ruti Campus,
Badalona, Barcelona,
Spain

María Martínez-Iniesta
Program in Molecular
Mechanisms and
Experimental Therapy
in Oncology (Oncobell),
IDIBELL, Hospitalet de
Llobregat, Barcelona,
Spain

Procure Program, Catalan
Institute of Oncology,
Hospitalet de Llobregat,
Barcelona, Spain

Catia Moutinho
Jordi Morata
Holger Heyn
CNAG-CRG, Centre for
Genomic Regulation (CRG),
Barcelona Institute of
Science and Technology
(BIST), Barcelona,
Catalunya, Spain

Ignacio Blanco
Programa
d'Assessorament i
Genètica Clínica, Hospital
Universitari Germans
Trias i Pujol, Badalona,
Barcelona, Spain

Edgar Creus-Bachiller
Hereditary Cancer
Program, Catalan Institute
of Oncology, IDIBELL,
Hospitalet de Llobregat,
Barcelona, Spain

Program in Molecular
Mechanisms and
Experimental Therapy
in Oncology (Oncobell),
IDIBELL, Hospitalet de
Llobregat, Barcelona,
Spain

Lourdes Farré
Program in Molecular
Mechanisms and
Experimental Therapy
in Oncology (Oncobell),
IDIBELL, Hospitalet de
Llobregat, Barcelona,
Spain

Procure Program, Catalan
Institute of Oncology,
Hospitalet de Llobregat,
Barcelona, Spain

Instituto Gonçalo Moniz.
Fundação Oswaldo Cruz
(FIOCRUZ), Brasil

Introduction

Malignant peripheral nerve sheath tumors (MPNSTs) are aggressive, locally invasive soft tissue sarcomas with a dismal prognosis, especially if complete surgical excision cannot be achieved.¹ Half of these tumors occur sporadically, whereas others appear in neurofibromatosis type 1 (NF1) patients.^{2,3} Focal radiotherapy is usually indicated, most importantly when margins remain affected after resection.⁴ Chemotherapy, including ifosfamide and doxorubicin, shows a modest response in a small percentage of patients.^{5,6} For unresectable, relapsed, and metastatic patients, there are no effective therapies and enrollment in clinical trials should be highly encouraged.

MPNST cells contain hyperploid and highly rearranged genomes, with a low mutation burden and few recurrent alterations.⁷ These recurrent mutations basically consist of the loss of particular tumor suppressor genes (TSGs). Lee *et al.* confirmed the implication of these TSGs,⁸ and established a core signature that consists in the recurrent inactivation of *NF1*, *CDKN2A/B*, components of the polycomb repressive complex 2 (*EED* and *SUZ12*), and *TP53*, a core signature that has been consolidated by others.^{9,10} Interestingly, there are drugs that target pathways activated due to the loss of these genes, such as MEK inhibitors (*NF1* loss), CDK4/CDK6 inhibitors (loss of *CDKN2A/B*), and BRD4 inhibitors (PRC2 loss of function). Some of these have been tested in pre-clinical or clinical contexts.¹¹⁻¹³ Results, although promising, seem to indicate that the combination of different drugs will be required for an effective therapy of MPNSTs.¹⁴

Advances in the molecular characterization of MPNST have increased our understanding of the molecular pathways that underlie this entity, and have opened up a new window of opportunities in personalized medicine. However, no clinical trial has demonstrated drug efficacy for unresectable MPNST, due partly to the low number of patients enrolled so far and the lack of a patient risk stratification system.^{2,3}

Herein, we present the case of an adolescent who developed a recurrent sporadic MPNST in which we tested the feasibility of using a patient derived orthotopic xenograft (PDOX) model and genomic characterization of the tumor to compile pre-clinical data in real time to guide the patient's therapy.

Methods

Patient

The patient was a previously healthy 14-year-old boy diagnosed with a brachial plexus MPNST, who relapsed 15 months later. A fragment of fresh tissue from the relapsed tumor was received for genomic analysis and PDOX generation. Informed consent was obtained and covered comprehensive genomic characterization of primary tumors from the patient as well as the development of mouse orthotopic animal models for pre-clinical use. The study received IDIBELL IRB (#PR213/13) and IDIBELL Animal Ethic Experimentation Committee (CEEA-IDIBELL) (#9111) approval.

Generation of PDOX models

Six-week-old male nude Harlan mice were used. A fragment of tumor (2–3 mm³) was engrafted in a single mouse (Passage 0) in the sciatic nerve (orthotopic engraftment) as previously described.¹⁵ Two months later, the tumor was expanded by resecting and engrafting into the two legs of seven new mice (Passage 1). Tumor resection was performed, opening a subcutaneous pocket with surgical scissors, an incision was made in the muscle to display and resect the MPNST. Animals were then sacrificed by cervical dislocation following the guidelines approved by our ethical committee. Representative fragments were either frozen in nitrogen or fixed in 10% buffered formalin and then processed for paraffin embedding.

The patient's lung metastasis was implanted orthotopically in mice lungs. Briefly, mice were anesthetized with a continuous flow of 1–3% isoflurane/oxygen mixture (2l/min) and subjected to right thoracotomy. Mice were situated in left lateral decubitus position, and a small transverse skin incision (~5–8 mm) was made in the right chest wall. Chest muscles were separated by a sharp dissection, and costal and intercostal muscles were exposed. An intercostal incision of 2–4 mm on the third or fourth rib on the chest wall was made and a small tumor piece of 2–4 mm³ was introduced into the chest cavity. The tumor specimen was anchored to the lung surface with Prolene 7.0 suture. Next, the chest wall incision was closed with surgical staples, and, finally, chest muscles and skin were closed. Mice were inspected twice a week and monitored for the presence of breathing problems.¹⁶ Seven months after engraftment, mice were sacrificed and tumors passed to another animal.

The mouse experiments were approved by the campus Animal Ethics Committee and complied with AAALAC (Association for Assessment and Accreditation of Laboratory Animal Care International) procedures.

Pre-clinical testing of drugs in PDOX models

Mimicking patient treatment in PDOX models. When tumors reached a homogenous size of 500–1000 mm³ after a month of growth, mouse tumors at passage 1 showing homogenous growth ($n=6$) were randomized into two groups: vehicle ($n=3$) and combined trametinib plus everolimus group ($n=3$) for 15 days. Mice were implanted with two tumors, one in each leg, and, after chemotherapy treatment, they were anesthetized and one tumor from each leg was resected while the other was allowed to regrow in live mice for 50 days. Subsequently, the regrowth tumors were engrafted in new nude mice to test new treatment schemes (Passage 2) (Table 1, Supplemental Materials and methods file). After treatment initiation, tumors were measured using a caliper every 2–3 days and tumor volume was calculated using the formula $v = (w^2 l/2)$, where l is the longest diameter and w the width.¹⁵

We administered all the diary compounds following a schedule of 5-days-on/2-days off. Partial response is considered when treatment does not completely eliminate the tumor.

Testing new treatments to guide future therapy. Considering the genomic alterations in the relapsed MPNST and bibliographic data, we started new treatment tests on the regrown PDOX after everolimus and trametinib treatment (Passage 2). We selected monotherapy treatments with bromodomain inhibitor JQ1 (PRC2 loss), palbociclib, a CDK4/6 inhibitor (*CDKN2A/B* loss), nab-paclitaxel, bevacizumab, and the combination of sorafenib plus doxorubicin and gemcitabine plus docetaxel. The treatments lasted 15 days, and, thereafter, tumors were allowed to regrow (Table 1).

Histological study

Representative fragments of the tumors (human and PDOX) were fixed, dehydrated, and embedded in paraffin. Tissue sections (3 μm) were hematoxylin-eosin stained for morphological analysis.

DNA preparation, SNP-array analysis, and exome sequencing

The GentraPuragene Kit (Qiagen, Hilden, Germany) was used for DNA isolation. SNP-array was performed using HumanOmniExpress-24v1-1 Beadchip as previously described.¹⁵ Genomic plots were created with karyoploteR.¹⁷

Exome sequence capture and amplification was performed using Agilent SureSelect Human All Exon kit (Agilent, Santa Clara, CA, USA) according to the manufacturer's instructions in the Centro Nacional de Análisis Genómico (CNAG). Sequencing was performed in a HiSeq2500 (Illumina, San Diego, CA, USA) with paired end 2x100 reads. We mapped the reads to the 1000 Genomes reference genome (hs37d5) using BWA MEM,¹⁸ and called variants using Strelka in germline mode.¹⁹ Variants were then normalized and annotated with annovar.²⁰

Table S1 in the supplemental material depicts the genome characterization performed in each sample.

Western blot

Samples for western blot were homogenized by a tissue lyser in radioimmunoprecipitation assay (RIPA) buffer containing complete protease inhibitor cocktail (Merck, Darmstadt, Germany) then centrifuged at 10,000 × g for 10 min to remove cellular debris.

Equivalent amounts of protein (20 μg) and the protein marker (NZYColour Protein Marker II, MB090, NZYtech, Lisbon, Portugal) were separated on 12% acrylamide gels (TGX Stain-Free™ FastCast™ Acrylamide kit; Bio-Rad, Hercules, CA, USA) gels. This technology contains trihalo compounds that react with tryptophan residues in a UV-induced reaction to produce fluorescence that can be detected by the ChemiDoc imaging system. Total protein was detected using the ChemiDoc imager in the membrane after transfer onto nitrocellulose membranes. Membranes were blocked for 1 h with bovine serum albumin (BSA) 5% and then incubated with primary antibody [H3K27me from Cell Signaling (9733) at 1:1000 dilution in 5% BSA; Cell Signalling Technology, Beverly, MA, USA]. The membranes were incubated for 1 h at room temperature with secondary antibody horseradish peroxidase-conjugated anti-rabbit (1:1000). Detection was conducted using SuperSignal West Femto chemiluminescent

August Vidal

Centro de Investigación Biomédica en Red de Cáncer (ICIBERONC), Spain

Department of Pathology, Hospital Universitari de Bellvitge (IDIBELL), Barcelona, Spain

Xenopat S.L., Business Bioincubator, Bellvitge Health Science Campus, Barcelona, Spain

Francisco Soldado

Pediatric hand surgery and microsurgery, Hospital Sant Joan de Déu, Universitat de Barcelona, Spain

Lucas Krauel

Pediatric Surgical Oncology, Pediatric Surgery Department, Hospital Sant Joan de Déu, Universitat de Barcelona, Spain

Mariona Suñol

Pathology Department, Hospital Sant Joan de Déu, Barcelona, Spain

*Both authors contributed equally to this manuscript and should be considered co-first authors

**Both authors should be considered senior and corresponding authors

Table 1. Drug treatments in the PDOX mouse model.

Treatment	Administration route	Dose (mg/kg)	Solvent	N° mice	Schedule
Trametinib	Oral	1	10% cremophor EL/10% PEG400	3	Daily
Everolimus	Intraperitoneal	5	2% DMSO/ carboxymethylcellulose	3	Daily
JQ1	Intraperitoneal	50	5%DMSO/5% dextrose	4	Daily
Nab-paclitaxel ^{&}	Intraperitoneal	20	50% ethanol/50% cremophor, diluted ¼ in saline	4	Daily
Bevacizumab	Intraperitoneal	5	PBS	3	Daily
Palbociclib	Oral	150	50 mM acetate buffer pH 4	3	Daily
Sorafenib	Oral	60	50% cremophor/50% ethanol	3	Daily
Doxorubicin*	Intraperitoneal	8	Saline	3	One dose
Gemcitabine*	Intraperitoneal	90	Saline	3	Every 4 days
Docetaxel*	Intravenous	15	Saline	3	Every 4 days

*Obtained from our hospital pharmacy.
[&]Nab-paclitaxel used is abraxane (the nano-particle of albumin-bound paclitaxel).
 PBS, phosphate-buffered saline; PDOX, patient-derived orthotopic xenograft.

substrate kits (Pierce Biotechnology Inc., Rockford, IL, USA) using the ChemiDoc imager.

Results

Patient description

The clinical history and evolution of the patient is summarized in Figure 1. Magnetic resonance imaging (MRI) revealed a large left brachial plexus tumor (Figure 2A) in a 14-year-old boy. Surgery was performed achieving gross total resection. Histological review confirmed MPNST. The patient met no criteria for NF1. Germline testing for *SMARCB1*, *NF1*, *CDKN2A*, *TP53*, *NF2*, *LZTR1*, *mTOR*, *MSH1*, and *MSH2* was negative. Upfront therapy included chemotherapy *as per* the International Society of Pediatric Oncology (SIOP) non-rhabdomyosarcoma (RMS) protocol; arm C (ifosfamide, vincristine, and actinomycin D) plus doxorubicin, followed by consolidation with focal radiotherapy (41 Grays). At the end of therapy, there was no evidence of disease. However, 8 months later, two cervical masses were detected (Figure 2B). Whole body FDG-PET/CT scan confirmed high metabolic activity in these two areas exclusively. A new, near total resection was achieved, and tumor relapse confirmed. During

surgery, tubes for brachytherapy were implanted. Fresh tissue was used for PDOX generation and genomic analysis. External re-irradiation was administered (normofractionated, total dose of 60 Grays). Based on pre-clinical data,²¹ and a clinical trial [ClinicalTrials.gov identifier: NCT03433183] where selumetinib was administered orally at a dose of 50 mg twice daily and sirolimus was administered orally at a dose of 4 mg once daily with a cycle 1 day loading dose of 12 mg, each cycle is considered as 28 days,²² the patient was started on a regimen of everolimus and trametinib (Figure 1).

PDOX generation and treatment mimicking the patient's drug scheme

Our experience in generating MPNST PDOX facilitated a rapid establishment of this patient's model in parallel with the patient's treatment.¹⁵ We implanted a fragment of relapsed tumor in a single mouse (Passage 0) in the sciatic nerve. Tumor growth was palpable 2 months after implantation. To try to better reproduce the patient's treatment, PDOX mice were treated with everolimus and trametinib in order to submit tumor xenografts to the same drug selection pressure as the patient's tumor. Since time is one of the key factors in real-time pre-clinical

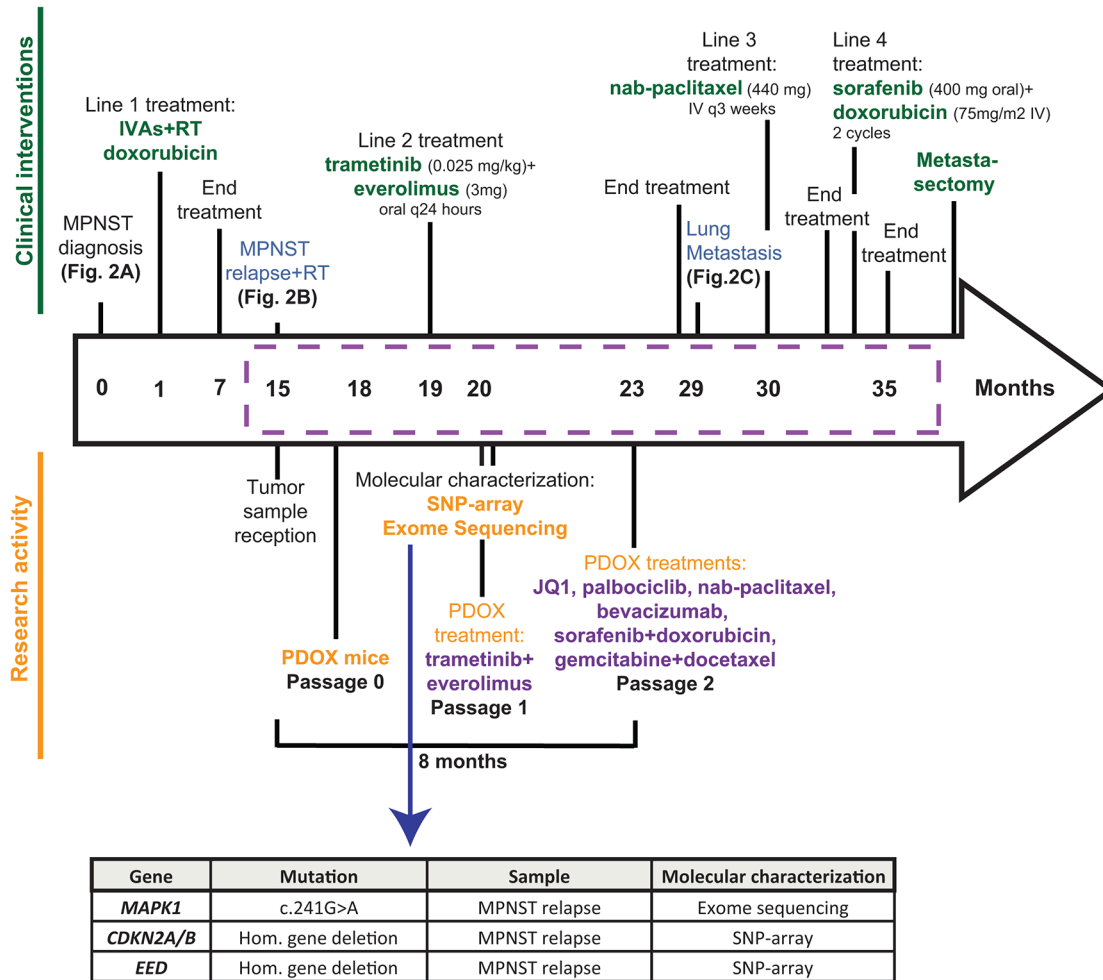


Figure 1. Timeline summary.

The clinical evolution and treatment of the patient is represented above the timeline arrow. Below is depicted the research activity performed. Discontinuous purple rectangle indicates time patient was attended at Hospital Sant Joan de Déu. Timeline is expressed in months.

treatments, and a treatment of 15–21 days in mice is considered sufficient to evaluate the pharmacological response, mice were treated for 15 consecutive days. At this point we observed a 35% tumor size-weight reduction compared with the control group (Figure 3), indicative of tumor response. After that, we let the tumors regrow for 50 days in order to use these regrown PDOXs for implanting new animals, for new drug treatments. In total, 5 months were necessary from the first tumor implantation until obtaining regrown PDOX tumors mirroring the patient's treatment. Comparative analysis of the patient's relapsed tumor with the PDOX model using SNP-array and histology analyses confirmed that the PDOX recapitulated human disease (Figure S1) as previously described.^{15,23,24} Overall, the genomic structure of the PDOX after treatment greatly

resembled the genomic structure of the patient's relapsed MPNST, although some small differences were observed such as the loss of chromosome 6q, already present in a subpopulation of the patient's relapsed MPNST, or the amplification of chromosomes 8q and 17p (Figure S1B).

Genomic analysis

Concomitant to PDOX development, SNP-array molecular karyotyping and exome sequencing was performed from the patient's relapsed MPNST. SNP-array identified a homozygous deletion in chromosome 11 involving the *EED* gene (Figure 4 and S2A), a component of the polycomb repressive complex 2 (PRC2). In agreement with this, decreased levels of H3K27me3 were detected in this tumor compared with

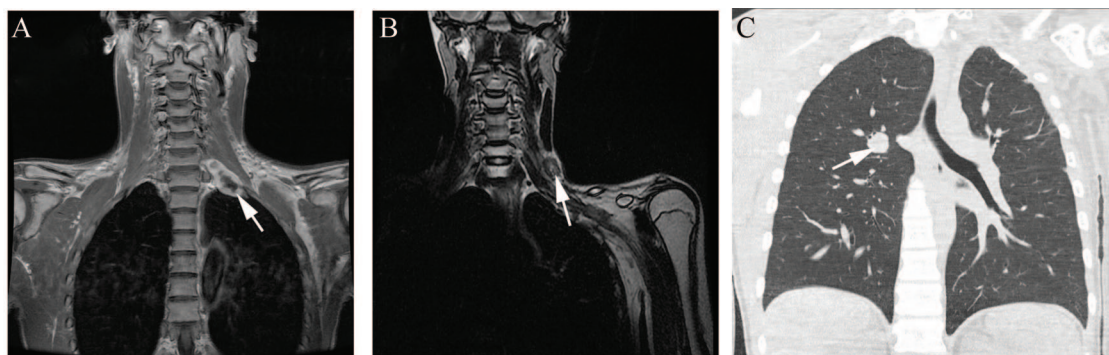


Figure 2. Images showing MPNST and relapses.

(A) Magnetic resonance imaging for diagnostic purposes revealing a large left brachial plexus tumor. The arrow points to the MPNST. (B) Neck and chest CT scan showing two nodes suspicious of local relapse. The arrow points to one node. (C) CT scan showing new lung nodule suspicious of metastatic relapse. The arrow points to a lung metastatic nodule.

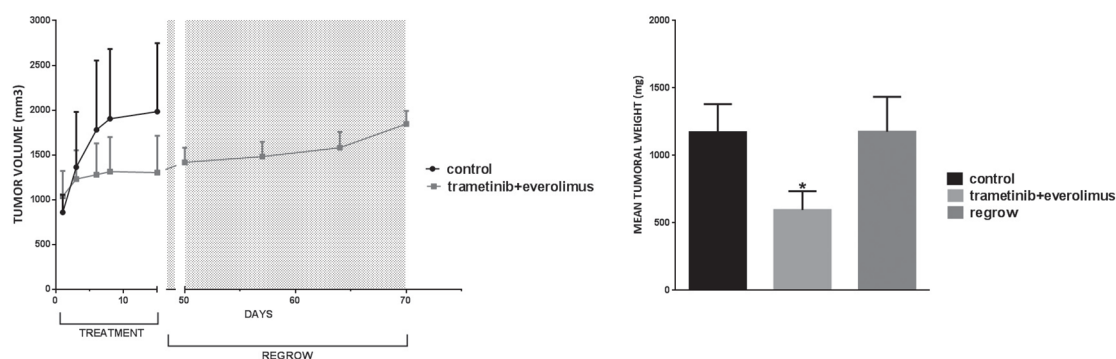


Figure 3. PDOX response to trametinib + everolimus regimen.

In the left panel, results are plotted as the average of tumor volume at different time points (days). In the right panel, the mean of the final tumor weight is plotted. Dashed grey areas denote time without treatment.

another MPNST with wild-type PRC2 (Figure S2B). In addition, a homozygous deletion in chromosome 9 was also identified, affecting the *CDKN2A* and *CDKN2B* tumor suppressor genes (Figure 4). Some other homozygous deletions were detected although they did not involve any other gene related with MPNST to date and are now under further investigation (Table S2). Also, exome sequencing identified several genetic variants (Table S3); *MAPK1* variant c.241G>A (p.Glu81Lys) was predicted as pathogenic, potentially resulting in the activation of the MAPK cascade.

Real-time treatments in mice to guide clinical-treatment decisions

Considering the genomic alterations identified in the patient's relapsed MPNST, data from the literature, availability of drugs, and time constraints, we designed a treatment scheme for performing on the regrown PDOX after everolimus-trametinib

(passage 2) consisting of monotherapies for: JQ1, a bromodomain inhibitor¹¹; palbociclib, a CDK4/6 inhibitor²⁵; nab-paclitaxel²⁶; bevacizumab²⁷; and the combinations of sorafenib plus doxorubicin¹⁵; and gemcitabine plus docetaxel.²⁸ Treatments were performed in two separate experiments according to drug availability and time restrictions (Figure 5A and B). The highest tumor reduction was achieved with the sorafenib plus doxorubicin combination (71%), followed by nab-paclitaxel (67%) and palbociclib (57%) (Figure 5A and B). No significant histological changes were found in residual regrown masses post-treatment (Figure S3). However, mice treated with sorafenib plus doxorubicin suffered significant weight loss. For nab-paclitaxel, several mice were re-treated with additional cycles, observing a clear stabilization of tumor size (Figure 5A) without achieving original tumor size. Hence, nab-paclitaxel seemed to be a good first option in the case of tumor relapse. In summary, we needed 8 months, and two mouse passages to complete this personalized co-clinical trial (Figure 1).

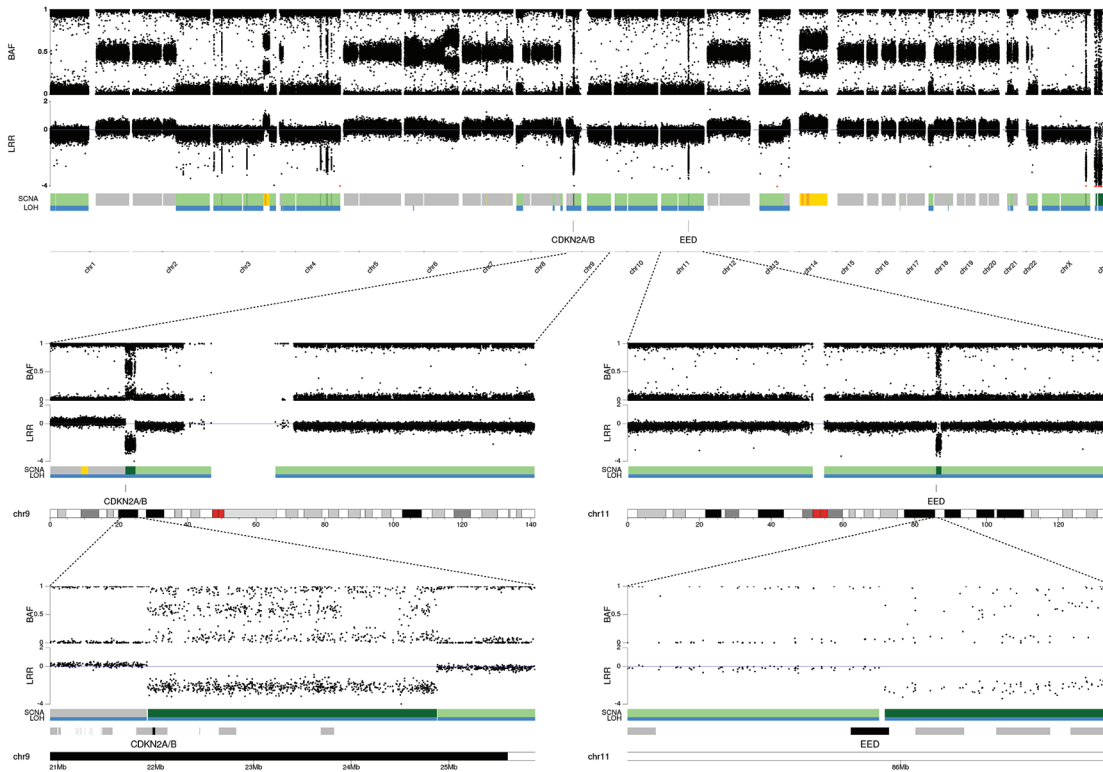


Figure 4. Molecular karyotyping by SNP-array analysis of the patient's relapsed MPNST.

Homozygous deletions encompassing the three last exons of *EED* (see Figure S2A for a detailed image) and the *CDK2NA/B* genes. Copy number variations are represented by a colored wide line under LRR (grey: 2n, yellow: > 2n [chromosomal gain]; light green: 1n (heterozygous loss); dark green: homozygous loss. LOH events are shown in blue.

Lung patient metastasis and treatment

After 11 months of treatment with everolimus and trametinib, a CT scan showed the appearance of new lung nodules, suspicious of metastatic relapse (Figure 2C). An excised nodule confirmed lung metastasis. We opted to treat the patient with nab-paclitaxel, which exhibited the highest tumor response and lowest toxicity in PDOX pre-clinical data. We observed an initial disease stabilization, but lung metastasis progressed 4 months later and treatment was switched to sorafenib and doxorubicin (Figure 1). This combination was the most effective treatment in our MPNST PDOX model, but the lung nodule progressed further on this regimen. Notably, the number of metastatic lesions did not increase. In this clinical scenario, the patient underwent serial metastasectomies at another institution and is currently disease free 46 months after the first relapse. With the aim of revealing new possibilities in the case of future tumor progression in the patient, the lung metastasis was implanted orthotopically in a new mouse, then the lung metastatic PDOX was sequenced. Lung metastasis grew slowly in the PDOX model, and tumor amplification was not feasible for performing new real-time

drug tests (Figure S4A–B). Interestingly, histological analysis of the mouse lungs did not identify additional metastatic dissemination, only confined local growth (Figure S4 C–F).

Discussion

We tested here the feasibility of using PDOX models to guide therapeutic decisions in real-time in a young patient with a relapsed MPNST. This patient's relapse was treated with a combination of MEK and mTOR inhibitors based on pre-clinical and clinical data [ClinicalTrials.gov identifier: NCT03433183].^{21,22} Accordingly, once the MPNST PDOX model was established (3 months), the same treatment was administered to the animals in order to emulate the potential molecular changes occurring in the patient's tumor due to treatment. The time constraints of a co-clinical pilot study made it very difficult to generate treatment-resistant PDOX models, so we developed the closest model possible to the patient's therapeutic scheme, while not compromising the collection of pre-clinical data during the patient's treatment in real-time. According to the genomic analysis of the patient's

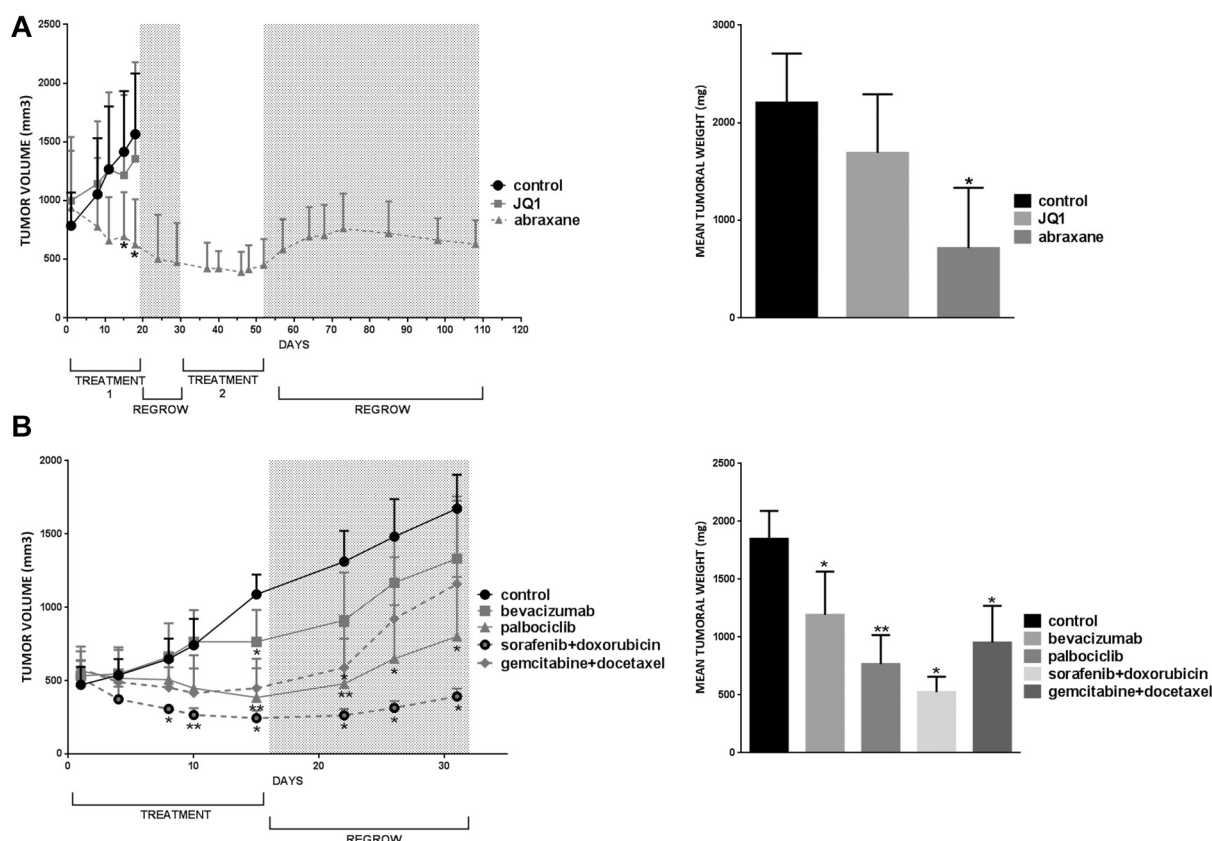


Figure 5. PDOX response to different drug treatment regimens.

In the left panels, results are plotted as the average of tumor volume at different time points (days). In the right panels, the mean of the final tumor weight is plotted. (A), JQ1 and Nab-paclitaxel. (B) bevacizumab, palbociclib, sorafenib + doxorubicin and gemcitabine + docetaxel. Dashed grey areas denote time without treatment.

relapsed tumor, published data, drug availability, and treatment possibilities, we first tested different monotherapy treatments and some co-treatments on regrown MPNST PDOX after trametinib and everolimus administration. Palbociclib (CDK4/6 inhibitor) showed significant tumor size reduction, in agreement with results presented in sarcomas.²⁵ JQ1 did not show the expected cytostatic effect observed previously *in vivo*,¹¹ although a recent *in vitro* study indicated that, in human NF1-derived MPNST samples, *BRD4* mRNA levels were not upregulated and that MPNST cell lines were relatively insensitive to the bromodomain inhibitor JQ1,²⁹ being in agreement with our PDOX results in this patient. In our study, we observed a significant tumor reduction, stabilizing tumor growth, when using nab-paclitaxel in monotherapy. Nab-paclitaxel, in combination with gemcitabine, has been described to produce a clinical benefit in 57% of patients with advanced soft-tissue sarcomas,³⁰ and is also now in a clinical trial [ClinicalTrials.gov identifier: NCT03524898].³¹ Moreover, the

combination of sorafenib plus doxorubicin decreased tumor size as previously described.¹⁵ No clear response was observed when treating with bevacizumab alone or with gemcitabine plus docetaxel. The combination of these three compounds was described as well tolerated and with activity in very high risk sarcomas, and can be further explored in future PDOX models.³² Interestingly, we completed our PDOX based-study 6 months before the disease progressed in the patient.

Lung metastasis was identified in this patient after 11 months of trametinib-everolimus treatment. Taking into consideration the PDOX results, we treated the patient with nab-paclitaxel. We observed stable disease, but lung metastasis progressed 4 months later. As a fourth line of treatment, sorafenib plus doxorubicin was administered with acceptable tolerance. Although the rate of tumor growth was reduced and no further dissemination was identified, multiple metastasectomies were performed to treat the patient.

As a future PDOX approach, it would be worthwhile to evaluate the efficacy and toxicity of co-treatments, capturing the three different molecular alterations identified in the patient's tumor (*MAPK1* activation, PRC2 and *CDKN2A/B* loss), some of which have previously been tested pre-clinically,^{11,33,34} and clinically in cancer patients ([ClinicalTrials.gov identifier: NCT03266159], [ClinicalTrials.gov identifier: NCT01841463])^{35,36} but we could not do this due to time limitations. In addition, our patient did not present local relapse, but lung metastasis and our PDOX model was not intended for modeling metastasis. To obtain the metastatic model, the primary tumor needs to be removed and then wait for metastasis to occur, an approach difficult to achieve in real-time co-clinical studies. Another limitation is that our PDOX model does not fully mimic the clinical course of the patient as the mice did not receive focal irradiation and brachytherapy as did the patient after relapse resection. Whereas radiotherapy treatments are frequent in clinical practice, they are difficult to implement in mice. Local irradiation is possible when the mouse is implanted in the sciatic nerve, but not in the lung. In order to optimize time and efforts, an ideal scenario would be the combination of PDOX with other strategies based on *in vitro* development of tumoroids or HDRA assays (histoculture drug response assay) that could be faster and cheaper. However *in vitro* studies do not obtain information regarding pharmacodynamic or pharmacokinetic aspects since most of them depend on the route of administration and solvents used. Finally, it is important to note that relapsed MPNST is a condition with a grim prognosis. Therapies directed by pre-clinical experiments may raise ethical considerations, and short- and long-term toxicities should be discussed with the patient.

Conclusion

In summary, our work demonstrates the feasibility of achieving a combined approach that includes the generation of PDOX models with the integration of genomic data used in real-time to guide critical clinical therapeutic decisions. However, the results observed in our model did not exactly recapitulate the patient's response. Certainly the time constraints of real-time pre-clinical studies greatly influence the possibility of generating the best models to mimic the patient's condition. However, the experience gained in this co-clinical pilot study could help us to better plan for a parallel modeling, to cover different potential scenarios, such as relapse or metastasis.

Future and more accurate models and tumor characterization may reduce the gap between the pre-clinical findings and patient outcomes. This could be achieved by improvement in mimicking a patient's real condition in PDOX (focal irradiation/brachytherapy and generation of a model with lung metastasis) as well as by enhancing genomic characterization by adding RNA sequencing and methylation data to our analysis that could provide a comprehensive variety of druggable targets to be tested in these models.

Acknowledgments

We thank CERCA Program/Generalitat de Catalunya for their institutional support. We thank all the patients and families with MPNST tumors. We would like to thank all Spanish Neurofibromatosis (NF) patients and NF associations for their continuing support and effort, in particular the Spanish Asociación de Afectados de Neurofibromatosis (AANF) and the Associació Catalana de les Neurofibromatosis (ACNefi). We also wish to thank the Catalan Institute of Oncology (ICO) and Institute for Health Science Research Germans Trias i Pujol (IGTP) Hereditary Cancer Program teams as well as the members of the Spanish CSUR of Phakomatoses.

Author contributions statement

JFR, AM, AVLL, BG, and CL conceived and design the study. AC, HS, MMI, ECB, FS, IB, MS and LF were involved in data acquisition. JFR, CM, JM, LK, GC, AV, AVLL and HH worked on analysis and interpretation. JFR, AM, AV, CL, BG, and ES performed the manuscript preparation. All authors revised the manuscript critically and approved the final version to be published.

Funding

The authors disclosed receipt of the following financial support for the research, authorship, and/or publication of this article: Contract grant sponsor: Supported by the Carlos III National Health Institute funded by FEDER funds – a way to build Europe – [PI19/00553, PI16/00563; PI16/01898 and CIBERONC]; the Government of Catalonia [Pla estratègic de recerca i innovació en salut (PERIS_MedPerCan and URDCat projects), 2017SGR1282 and 2017SGR496]; the Fundación PROYECTO NEUROFIBROMATOSIS (FPNF), the Scientific Foundation Asociación Española Contra el Cáncer and Fundació La Marató de TV3. Xenopat S.L (www.xenopat.com) supported the cost of several experiments as a social corporate

responsibility action. This study was performed without any cost/charge for the patient.

Conflict of interest statement

The authors declared no potential conflicts of interest with respect to the research, authorship, and/or publication of this article.

ORCID iD

Conxi Lázaro  <https://orcid.org/0000-0002-7198-5906>

Supplemental material

Supplemental material for this article is available online.

References

1. Scaife CL and Pisters PW. Combined-modality treatment of localized soft tissue sarcomas of the extremities. *Surg Oncol Clin N Am* 2003; 12: 355–368.
2. Kim A, Stewart DR, Reilly KM, *et al.* Malignant peripheral nerve sheath tumors state of the science: leveraging clinical and biological insights into effective therapies. *Sarcoma* 2017; 2017: 7429697.
3. Reilly KM, Kim A, Blakely J, *et al.* Neurofibromatosis type 1-associated MPNST state of the science: outlining a research agenda for the future. *J Natl Cancer Inst* 2017; 109: dxj124.
4. Stucky CC, Johnson KN, Gray RJ, *et al.* Malignant peripheral nerve sheath tumors (MPNST): the mayo clinic experience. *Ann Surg Oncol* 2012; 19: 878–885.
5. Ferrari A, Miceli R, Rey A, *et al.* Non-metastatic unresected paediatric non-rhabdomyosarcoma soft tissue sarcomas: results of a pooled analysis from United States and European groups. *Eur J Cancer* 2011; 47: 724–731.
6. Carli M, Ferrari A, Mattke A, *et al.* Pediatric malignant peripheral nerve sheath tumor: the Italian and German soft tissue sarcoma cooperative group. *J Clin Oncol* 2005; 23: 8422–8430.
7. Lazar AJ, McLellan MD, Bailey MH, *et al.* Comprehensive and integrated genomic characterization of adult soft tissue sarcomas. *Cell* 2017; 171: 950–965.e28.
8. Lee W, Teckie S, Wiesner T, *et al.* PRC2 is recurrently inactivated through EED or SUZ12 loss in malignant peripheral nerve sheath tumors. *Nat Genet* 2014; 46: 1227–1232.
9. Sohler P, Luscan A, Lloyd A, *et al.* Confirmation of mutation landscape of NF1-associated malignant peripheral nerve sheath tumors. *Genes Chromosomes Cancer* 2017; 56: 421–426.
10. Brohl AS, Kahen E, Yoder SJ, *et al.* The genomic landscape of malignant peripheral nerve sheath tumors: diverse drivers of Ras pathway activation. *Sci Rep* 2017; 7: 14992.
11. De Raedt T, Beert E, Pasmant E, *et al.* PRC2 loss amplifies Ras-driven transcription and confers sensitivity to BRD4-based therapies. *Nature* 2014; 514: 247–251.
12. Jessen WJ, Miller SJ, Jousma E, *et al.* MEK inhibition exhibits efficacy in human and mouse neurofibromatosis tumors. *J Clin Invest* 2013; 123: 340–347.
13. Dombi E, Baldwin A, Marcus LJ, *et al.* Activity of selumetinib in neurofibromatosis type 1-related plexiform neurofibromas. *N Engl J Med* 2016; 375: 2550–2560.
14. Kim A and Pratilas CA. The promise of signal transduction in genetically driven sarcomas of the nerve. *Exp Neurol* 2018; 299: 317–325.
15. Castellsagué J, Gel B, Fernández-Rodríguez J, *et al.* Comprehensive establishment and characterization of orthoxenograft mouse models of malignant peripheral nerve sheath tumors for personalized medicine. *EMBO Mol Med* 2015; 7: 608–627.
16. Ambrogio C, Carmona FJ, Vidal A, *et al.* Modeling lung cancer evolution and preclinical response by orthotopic mouse allografts. *Cancer Res* 2014; 74: 5978–5988.
17. Gel B and Serra E. karyoploteR: an R/Bioconductor package to plot customizable genomes displaying arbitrary data. *Bioinformatics* 2017; 33: 3088–3090.
18. Li H. Aligning sequence reads, clone sequences and assembly contigs with BWA-MEM. *arXiv Preprint arXiv:1303.3997*, 2013.
19. Kim S, Scheffler K, Halpern AL, *et al.* Strelka2: fast and accurate calling of germline and somatic variants. *Nat Methods* 2018; 15: 591–594.
20. Wang K, Li M and Hakonarson H. ANNOVAR: functional annotation of genetic variants from high-throughput sequencing data. *Nucleic Acids Res* 2010; 38: e164.
21. Watson AL, Anderson LK, Greeley AD, *et al.* Co-targeting the MAPK and PI3K/AKT/mTOR pathways in two genetically engineered mouse models of Schwann cell tumors reduces tumor grade and multiplicity. *Oncotarget* 2014; 5: 1502–1514.
22. ClinicalTrials.gov. SARC031: MEK inhibitor selumetinib (AZD6244) in combination with

- the mTOR inhibitor sirolimus for patients with malignant peripheral nerve sheath tumors, <https://clinicaltrials.gov/ct2/show/NCT03433183?term=03433183&rank=1> (2018, accessed March 2020).
23. Vidal A, Muñoz C, Guillén MJ, *et al.* Lurbinectedin (PM01183), a new DNA minor groove binder, inhibits growth of orthotopic primary graft of cisplatin-resistant epithelial ovarian cancer. *Clin Cancer Res* 2012; 18: 5399–5411.
 24. Moiola CP, Lopez-Gil C, Cabrera S, *et al.* Patient-derived xenograft models for endometrial cancer research. *Int J Mol Sci* 2018; 19: 2431.
 25. Perez M, Muñoz-Galván S, Jiménez-García MP, *et al.* Efficacy of CDK4 inhibition against sarcomas depends on their levels of CDK4 and p16ink4 mRNA. *Oncotarget* 2015; 6: 40557–40574.
 26. Apice G, Pizzolorusso A, Di Maio M, *et al.* Confirmed activity and tolerability of weekly paclitaxel in the treatment of advanced angiosarcoma. *Sarcoma* 2016; 2016: 6862090.
 27. Somaiah N and von Mehren M. New drugs and combinations for the treatment of soft-tissue sarcoma: a review. *Cancer Manag Res* 2012; 4: 397–411.
 28. Maki RG. Gemcitabine and docetaxel in metastatic sarcoma: past, present, and future. *Oncologist* 2007; 12: 999–1006.
 29. Amirnasr A, Verdijk RM, van Kuijk PF, *et al.* Expression and inhibition of BRD4, EZH2 and TOP2A in neurofibromas and malignant peripheral nerve sheath tumors. *PLoS One* 2017; 12: e0183155.
 30. Sonnenblick A, Eleyan F, Peretz T, *et al.* Gemcitabine in combination with paclitaxel for advanced soft-tissue sarcomas. *Mol Clin Oncol* 2015; 3: 829–832.
 31. ClinicalTrials.gov. NAPAGE: NAb-Paclitaxel and GEmcitabine in Advanced Soft Tissue Sarcoma, <https://clinicaltrials.gov/ct2/show/NCT03524898> (2018, accessed March 2020).
 32. Kuo C, Kent PM, Logan AD, *et al.* Docetaxel, bevacizumab, and gemcitabine for very high risk sarcomas in adolescents and young adults: a single-center experience. *Pediatr Blood Cancer* 2017; 64.
 33. Bolin S, Borgenvik A, Persson CU, *et al.* Combined BET bromodomain and CDK2 inhibition in MYC-driven medulloblastoma. *Oncogene* 2018; 37: 2850–2862.
 34. Lee MS, Helms TL, Feng N, *et al.* Efficacy of the combination of MEK and CDK4/6 inhibitors in vitro and in vivo in KRAS mutant colorectal cancer models. *Oncotarget* 2016; 7: 39595–39608.
 35. ClinicalTrials.gov. A dose escalation study to investigate the safety, pharmacokinetics (PK), pharmacodynamics (PD), and clinical activity of GSK525762 plus trametinib in subjects with solid tumors, <https://clinicaltrials.gov/ct2/show/NCT03266159>. (2017, accessed March 2020).
 36. ClinicalTrials.gov. Study of an oral CDK inhibitor administered with an oral BRAF inhibitor in patients with advanced or inoperable malignant melanoma with BRAF mutation, <https://clinicaltrials.gov/ct2/show/NCT01841463> (2013, accessed March 2020).

Visit SAGE journals online
[journals.sagepub.com/
 home/tam](https://journals.sagepub.com/home/tam)

 SAGE journals